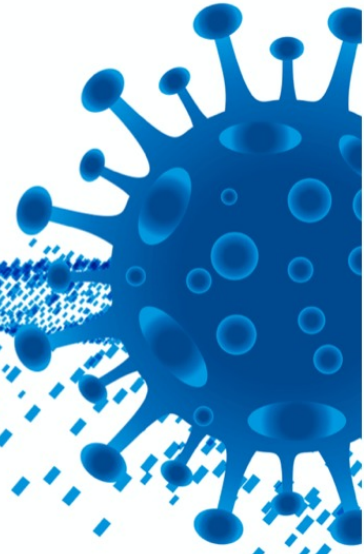


COVID-19 **MD**



COVID-19 | Orthodontics Extension

Clinical Guidelines Dentistry

| Update

Scientific paper drawn up by the COVID-19 MD group aiming the dissemination of the knowledge about the clinical practice in dentistry in the context of COVID-19.

The expression *Clinical Guidelines* refers to a scientific methodology and type of publication arising from it. This document should not, thus, be understood as legislation nor as any type of imposition of regulatory or legal nature. It is a scientific contribution to the broadening of the knowledge about the professional practice in the context of COVID-19, hopefully serving its recipients.

The contents contained in this extension do not replace the reading of the full document^[1], but rather complement it in a particular way in which concerns the treatment of the pediatric patient.

Authors	5
Authors Orthodontics Extension	9
Advisory Board	10
Objectives	13
Scientific Relevance	13
Topic/Disease	14
Category	14
Target Population	14
Recipients of the Guidelines	14
Introduction	15
The Stages of Pre-Intervention	17
What is within the reach of the patients to adhere to in a household context?	17
Which recommendations concerning oral hygiene / food should be conveyed to the patients who are wearing fixed and removable appliances?	17
How should we reorganize the process of scheduling orthodontics consultations?	19
Which protocols must be guaranteed in order to benefit from the consultation in the form of telemedicine/virtual orthodontics?	19
In the framework of telemedicine, which procedures of the orthodontics consultation can be planned?	21
What are the constraints in the access to the orthodontics consultation?	21
The Stages of Peri-Intervention	24
Which type of PPE must be worn in an orthodontics consultation?	24
What should the course of action regarding urgent situations or non-urgent appointments in orthodontics consultation be like?	25
Removable appliance	26
Fixed appliance	26
How should the disinfection of the removable braces be performed?	29
How should the arches be disinfected in the course of the extraoral manipulation?	29
How should steel wires, elastic chains and elastomers be manipulated?	29
The Stages of Post-Intervention	32
Which procedure should be adopted in the sterilization of the orthodontic cutting pliers?	32
What care should you have for the other instruments and specific orthodontic material in order to reduce the risk of nosocomial infection?	33
How can we avoid cross infection with the photo equipment?	34
How can you disinfect intraoral mirrors?	35
Conclusion	38
Bibliography	39

Authors

Fernando Guerra

Dentist

Full Professor at the Faculty of Medicine of the University of Coimbra

Director of the Center of Research and Innovation in Dental Sciences of the Faculty of Medicine of the University of Coimbra

<https://orcid.org/0000-0001-8780-9379>

António Duarte Mata

Dentist

Full Professor at the Faculty of Dentistry of the University of Lisbon

Coordinator of the LIBPhys-UL Research Unit-UID/FIS/04559/2013, Faculty of Dentistry, University of Lisbon

Main Researcher of the Research Group in Oral Biochemistry and Biology, GIBBO FMDUL

<https://orcid.org/0000-0003-1474-2681>

Alexandra Vinagre

Dentist

Guest Assistant at the Faculty of Medicine of the University of Coimbra

Researcher at the Center of Research and Innovation in Dental Sciences of the Faculty of Medicine of the University of Coimbra

<https://orcid.org/0000-0001-6929-3807>

Ana Luísa Costa

Dentist

Assistant Professor at the Faculty of Medicine of the University of Coimbra

Researcher at the Center of Research and Innovation in Dental Sciences of the Faculty of Medicine of the University of Coimbra

<https://orcid.org/0000-0002-4102-1719>

Andreia Luís Vieira

Dentist

Guest Assistant at the Faculty of Dentistry of the University of Lisbon

Researcher of the Research Group in Oral Biochemistry and Biology, GIBBO FMDUL

<https://orcid.org/0000-0002-3271-8645>

Carlos Falcão

Dentist

Assistant Professor at the Faculty of Health Sciences of the Fernando Pessoa University

<https://orcid.org/0000-0001-8031-6176>

Carlota Duarte de Mendonça

Dentist

Researcher of the Research Group in Oral Biochemistry and Biology, GIBBO FMDUL

<https://orcid.org/0000-0001-6133-1995>

Catarina Chaves

Doctor

Hospital Assistant in Clinical Pathology

Head of the Laboratory of General Bacteriology

Service of Clinical Pathology, Medical Teaching Hospital of Coimbra

<https://orcid.org/0000-0003-0131-5728>

David Herrera

Odontologist

Professor at the Faculty of Dentistry of the Complutense University of Madrid

Vice-Dean at the Faculty of Dentistry of Madrid, Spain

<https://orcid.org/0000-0002-5554-2777>

Isabel Poiares Baptista

Dentist

Assistant Professor at the Faculty of Medicine of the University of Coimbra

Researcher at the Center of Research and Innovation in Dental Sciences of the Faculty of Medicine of the University of Coimbra

<https://orcid.org/0000-0003-4503-5365>

Ivan Toro

Dentist

<https://orcid.org/0000-0002-0437-4152>

João Braga

Dentist

Assistant Professor at the Faculty of Dentistry of the University of Oporto

<https://orcid.org/0000-0002-0895-1009>

João Carlos Ramos

Dentist

Assistant Professor at the Faculty of Medicine of the University of Coimbra

Researcher at the Center of Research and Innovation in Dental Sciences of the Faculty of Medicine of the University of Coimbra

<https://orcid.org/0000-0003-1965-1092>

João Miguel Santos

Dentist

Assistant Professor at the Faculty of Medicine of the University of Coimbra

Researcher at the Center of Research and Innovation in Dental Sciences of the Faculty of Medicine of the University of Coimbra

<https://orcid.org/0000-0002-2865-9689>

João Miguel Silveira

Dentist

Assistant Professor at the Faculty of Dentistry of the University of Lisbon

Researcher at the LIBPhys-UL Research Unit-UID/FIS/04559/2013, Faculty of Dentistry, University of Lisbon

Researcher of the Research Group in Oral Biochemistry and Biology, GIBBO FMDUL

<https://orcid.org/0000-0001-9366-0662>

João Paulo Tondela

Dentist

Assistant Professor at the Faculty of Medicine of the University of Coimbra

Researcher at the Center of Research and Innovation in Dental Sciences of the Faculty of Medicine of the University of Coimbra

<https://orcid.org/0000-0003-0787-7713>

Paulo Palma

Dentist

Guest Assistant Professor at the Faculty of Medicine of the University of Coimbra

Researcher at the Center of Research and Innovation in Dental Sciences of the Faculty of Medicine of the University of Coimbra

<https://orcid.org/0000-0003-4730-8072>

Pedro Nicolau

Dentist

Associate Professor at the Faculty of Medicine of the University of Coimbra

Researcher at the Center of Research and Innovation in Dental Sciences of the Faculty of Medicine of the University of Coimbra

<https://orcid.org/0000-0001-7900-4482>

Pedro Sousa Gomes

Dentist

Associate Professor at the Faculty of Dentistry of the University of Oporto

Researcher at the Center of Research Bone Lab of the Faculty of Dentistry of the University of Oporto
<https://orcid.org/0000-0001-5365-2123>

Ricardo Dias

Dentist

Guest Assistant at the Faculty of Medicine of the University of Coimbra

Researcher at the Center of Research and Innovation in Dental Sciences of the Faculty of Medicine of the University of Coimbra

<https://orcid.org/0000-0002-0824-9754>

Salomão Rocha

Dentist

Guest Assistant at the Faculty of Medicine of the University of Coimbra

Researcher at the Center of Research and Innovation in Dental Sciences of the Faculty of Medicine of the University of Coimbra

<https://orcid.org/0000-0002-5702-333X>

Sérgio Matos

Dentist

Assistant Professor at the Faculty of Medicine of the University of Coimbra

Researcher at the Center of Research and Innovation in Dental Sciences of the Faculty of Medicine of the University of Coimbra

<https://orcid.org/0000-0002-2548-4326>

Version 1.1.1 | May, 20th of 2021. All rights reserved.

Authors | Orthodontics Extension

Francisco do Vale

Dentist

Assistant Professor at the Faculty of Medicine of the University of Coimbra

Researcher at the CIROS, FMUC

Director of the Orthodontic Institute of the FMUC

Coordinator of the Integrated Masters degree in Dentistry at the Faculty of Medicine of the University of Coimbra

<https://orcid.org/0000-0003-2615-2929>

Luísa Maló

Dentist

Assistant Professor at the Faculty of Medicine of the University of Coimbra

Researcher at the CIROS, FMUC

Orthodontic Institute, FMUC

<https://orcid.org/0000-0001-9218-8001>

Sónia Alves Pereira

Dentist

Assistant Professor at the Faculty of Medicine of the University of Coimbra

Researcher at the CIROS, FMUC

<https://orcid.org/0000-0003-2409-5748>

Version 1.1.1 | May, 20th of 2021. All rights reserved.

Advisory Board

Doctor and Professor Ana Lúcia de Pereira Neves Messias

Assistant Professor at the Faculty of Medicine of the University of Coimbra

Professor Professor Aníbal Diógenes

Associate Professor at the University of Texas, *Health Center of San Antonio*, United States of America

Doctor and Professor António Vaz Carneiro

Full Professor of Medicine at the Faculty of Medicine of the University of Lisbon and Director of Cochrane Portugal

Doctor and Professor Carlos Robalo Cordeiro

Director of the Faculty of Medicine of the University of Coimbra

Doctor and Professor Duarte Marques

Representative of the Portuguese Society of Stomatology and Dental Medicine

Doctor and Professor Gil Alcoforado

Full Professor

Doctor and Professor Ion Zabalegui

Guest Professor at the University *Complutense* of Madrid, Spain

Doctor José Manuel da Costa Rodrigues de Oliveira

Dentist

Doctor José Frias Bulhosa

Master's degree in public health from the Faculty of Medicine of the University of Coimbra; Representative of the Portuguese Association of Public Service Dentists (APOMED-SP)

Doctor Luís António Silva Ferreira

Dentist

Doctor and Professor Luís Pires Lopes

Head of the Faculty of Dentistry of the University of Lisbon

Doctor and Manuel Gameiro

Full Professor at the Mechanical Engineering Department of the University of Coimbra

Doctor and Professor Maria Helena Raposo Fernandes

Full Professor at the Faculty of Dentistry of the University of Porto

Doctor and Professor Mário Bernardo

Coordinator of the Integrated Master Degree in Dentistry at the Faculty of Dentistry at the University of Lisbon

Doctor and Professor Mariano Sanz

Full Professor at the University Complutense of Madrid, Spain

Doctor and Professor Marlene Barros

Head of the Faculty of Dentistry of the Catholic University of Portugal

Doctor Paulo Manuel de Oliveira Nunes

Dentist

Doctor Nuno Ventura

Dentist

Doctor Ricardo Jorge Martins

Dentist

Doctor and Professor Sandra Gavinha

Head of the Faculty of Health Sciences of Fernando Pessoa University

Preliminary remark

Despite the appearance of COVID-19 date a year, there is still a gap in the quality of the scientific evidence that is published. The amount of information in this area is exorbitant, in a desperate attempt to find answers to a virus that is still so unknown to us. As such, this update followed the methodology of the initially published NOC (protocol provided by the English National Institute for Health and Care Excellence (NICE), namely the Interim process and methods for developing rapid guidelines on COVID-19 ([nice.org.uk](https://www.nice.org.uk) ^[2]).

Objectives

Identify and classify the risks of acquisition and spread of SARS-CoV-2 in the context of pre-, peri-, and post-intervention in oral health.

Produce recommendations on how to act in pre-, peri-, and post-intervention in oral health for every element present at the clinical theatre aiming to minimize the risk of acquisition and/or spread of SARS-CoV-2.

Scientific Relevance

Given that:

Over the course of the actual pandemic of COVID-19 several sources have identified the activity of dentistry as being at the top of the pyramid as far as the risk of acquisition and spread of the virus SARS-CoV-2 is concerned due to the enormous generation of aerosols which characterize it, the Portuguese government having determined the provisional closure of the clinics of dentistry and stomatology.

Currently, there are no national Clinical Guidelines which convey recommendations on how to act on every step of pre-, peri-, and post-intervention in dentistry aiming the prevention of the acquisition and spread of the virus SARS-CoV-2.

There is, therefore, the need to create these Clinical Guidelines as a set of recommendations on how to act, allowing the return to the activity of dentistry in safe conditions of those involved at the clinical theater, whether they are professionals, partners of the sector or the user population in general.

It should be noted that the Clinical Guidelines intend to support the clinical decision. It is not a document which might replace the clinical decision, but rather one which the practitioner can lean on whenever he/she must choose the best course of action considering his/her experience, the patient's specific interests and the very clinical theater in which the practice takes place. It is not, therefore, a document which aims the tyrannization of evidence over the choice, but one which only allows to decide taking into consideration the greatest robustness of evidence possible.

Topic/Disease

COVID-19 - Minimization of the risk of acquisition and spread of the disease in dentistry in the context of the pandemic.

Category

These are Clinical Guidelines on clinical governance advice, best practice and clinical safety.

Target Population

Patients of dentistry and members of the oral health staff.

Recipients of the Guidelines

All the parties concerned, namely: dentists, stomatologists, odontologists, pharmacists, nurses, oral hygienists, dental prosthetic technicians, clinic's support auxiliary personnel, receptionists, administrative staff, diagnosis and therapy technicians, senior technicians of safety and hygiene at work, technicians of clinical analysis, suppliers of dental material and equipment, medical sales representatives, maintenance technicians, waste collection technicians, professional associations, scientific societies, education institutions, students of dentistry, hospitals, insurance companies and conventions, commercial and industrial partners, policy makers, Portuguese Dental Association, Portuguese Health Authority, sectoral regulatory bodies and patients.

Introduction

The high potential for transmission of the new SARS-CoV-2 coronavirus has led the WHO to declare the public health state of emergency on an international scale in the end of January^[3].

Oral health professionals present a high risk of contagion due to the close contact with the patient's oral, nasal and ocular mucosae during the clinical practice. Additionally, the methodologies that generate the production of aerosols, a routine situation in some orthodontic procedures, are also considered an important transmission route of the infection by SARS-CoV-2^[4-6].

COVID-19 has been reported to be detected in asymptomatic patients and children, the majority of patients in pediatric and orthodontic clinics who place orthodontists and pediatric dentists at great risk^[7].

The use of aligners is preferable to fixed treatment with the advantages: less control visits, monitoring by virtual means, greater precision in treatment planning by digital means, better control of the plaque and less iatrogenic effects as white lesions and root resorption^[8].

The susceptibility to the infection by SARS-CoV-2 is transversal to every age group, although the symptoms among children and teenagers are not, as a rule, as severe as among adults. However, different studies reported that asymptomatic children may present an infection by SARS-CoV-2, being, for that reason, a risk group for its transmission. Additionally, the virus is highly contagious during the incubation period which may be longer in this age group. We must also take into consideration that the patient and his/her parents may potentially omit in the clinical history the presence of the disease, thus contributing to its dissemination^[9-14].

This age group formed by children and teenagers encompasses a considerable proportion of orthodontic patients. On the other hand, the orthodontics consultation allows the treatment of a high number of patients on a daily basis. Thus, in order to face this infection by SARS-CoV-2, a highly contagious one, it is of extreme importance to reassess the program of prevention and control of infection in orthodontic practice^[6, 15].

Orthodontic problems, like the problems of dentistry, in general, are mostly urgencies rather than real emergencies, wherefore a videocall or message with an attached photo may prove a possible option to assess the case^[16, 17].

The Stages of Pre-Intervention

What is within the reach of the patients to adhere to in a household context?

Answer: Fixed orthodontic braces favor the retention of bacterial plaque making oral hygiene difficult and increasing, consequently, the risk of development of carious lesions or of periodontal pathology, particularly of gingivitis. The educational strengthening aimed at increasing the cooperation of patients in complying with good practice of oral hygiene is of the essence and must be performed in every consultation, if necessary, complemented by information leaflets. Different strategies may be adopted to control short-term oral hygiene, namely by encouraging the use of bacterial plaque revealers, regular sending of warning messages, self-photograph and/or video sharing with the orthodontist or the oral hygienist on suitable platforms, being possible to receive feedback regarding the oral condition and advice tailored to every particular situation. The strengthened care regarding food habits must be stressed, since it may help containing some urgent incidents, which must be avoided even more in this pandemic period we are going through. Last but not least, it must also be oral health professionals' mission to encourage the implementation of a correct and frequent hand hygiene and the use of mask in public places, knowing that those are the fundamental strategic way to prevent the transmission and epidemic dissemination of COVID-19^[18-21]. *(Level Ib, Class I)*

Which recommendations concerning oral hygiene / food should be conveyed to the patients who are wearing fixed and removable appliances?

Answer: During the period of treatment with the fixed orthodontic braces, the mouth is full of devices, like brackets, arches and bands, which favor the bacterial plaque buildup. That way, keeping a proper oral hygiene becomes more important and, consequently, more difficult. The patient must be told to give closer attention to these areas during his/her oral hygiene, stressing the following points:

- Brush using an orthodontic brush, at least, twice a day or after the meals for two minutes, using additionally a single tufted brush and/or an interdental spiral brush to sanitize the brackets and the spaces in between the teeth;
- Use dental floss once a day. Thread a suitable dental floss behind the arch and in between the brackets, so that it does not dislocate any wire which is present, like the extremities of metallic ligature ties. Additionally, use also an irrigator as a complement of hygiene;
- Use a daily mouthwash with fluorine. It will allow to minimize the risk of leucomas in enamel secondary to the demineralization process and of dental carious lesions;
- Oral hygiene kit. Patients must always carry around an oral hygiene travel kit containing: a small brush, an interdental spiral brush, a dental floss and orthodontic wax^[18, 22].

The functional removable braces or base plate type, made of acrylic, with or without added metallic elements, must never be left to dry since it will lead to the deposition of tartar and biofilm. Therefore, they must be kept in the mouth or submerged in a liquid medium when they are not being used. They can be sanitized daily with the brush and the toothpaste, and additionally they can be disinfected once or twice a week with a chlorhexidine mouthwash at 0,12% or using effervescent tablets which are effective against *Streptococcus Mutans*^[23, 24].

The care with what you eat is one of the focal points throughout the treatment with a fixed brace. You must avoid cariogenic food or that which is likely to damage the fixed braces, like sticky food items such as toffees, chewing gums, gums, among others, which may be lodged in between the brackets and prove difficult to remove; hard food items such as bread crust or cornbread, toasts, raw apples or carrots, which must be cut into smaller pieces, since they tend to dislodge the wires and to damage the fixed braces. The patient who is wearing a fixed brace must also avoid to introduce objects in his/her mouth, such as pencils or pens, since these may detach the brackets or dislocate the arches. The orthodontic wax must be used whenever a wire is dislodged and hurts the mucosae.

The non-compliance with these recommendations may imply an extension of the treatment's duration and force extra urgent consultations, which must be minimized^[22, 25].

(Level Ib, Class I)

How should we reorganize the process of scheduling orthodontics consultations?

Answer: Concerning the orthodontics consultation, it is advisable the development of internal scheduling norms between the orthodontist and his/her team that fit the type of procedure to be performed on every patient. Invariably, the required consultation time in this pandemic period is necessarily longer than what was predetermined before. This way, the number of patients that can be treated daily will necessarily be smaller. The adequate amount of time required for each orthodontic procedure (i.e., placement of fixed braces, placement of removable appliances, removal of braces and placement of retainers; follow-up visits to check on the fixed braces; follow-up visits to check on the removable braces, follow-up visits to check on the aligners, etc) must be predetermined in order to expedite and facilitate the scheduling of consultations, complying with the standards of infection control in this pandemic phase.

Since aerosol generation is not frequent at the orthodontics consultation, most critical procedures, like the placement and removal of braces, may be schedule at end of the morning or late afternoon, allowing for a longer break period of the office after consultation, allowing a greater effectiveness in the decontamination and aeration of the physical space. However, the aerosols produced during the removal of the orthodontic appliance lead to the release of particles essentially located near the patient, operator and assistant. The removal of the composite with a low rotation "handpiece", without water, with surgical aspiration does not produce contamination by wide dispersion, and these aerosols are also circumscribed^[26-41]. (*Level III, Class IIa*)

Which protocols must be guaranteed in order to benefit from the consultation in the form of telemedicine/virtual orthodontics?

Answer: During the pandemic phase, there might be some retraction, by some patients, when it comes to schedule a dentistry appointment in general, as well as a orthodontics consultation in particular. Thus, resorting to teleconsulting may be an alternative in the schedule management, minimizing the patient's risk of exposure in the physical space of the consultation and maximizing the physician's response capacity, bearing in mind, however, the constraints inherent to this type of consultation^[8, 42-44].

Portugal has more than 9 million cell phone users, representing 96,5% of the Portuguese aged 10 or more (2018). Of these, 7,2 million use internet in their cell phones (2018), resorting to any form of social media to contact their family, friends and acquaintances^[45,46].

The virtual orthodontic assistance can be carried out by photos or videos sent by the patient or by videocall. There are several platforms/applications which allow these virtual consultations and, therefore, must be assessed by every clinical unit. The dissemination of instant messaging applications like Whatsapp Messenger, Telegram Messenger or Snapchat, among users of every age as a way of virtual contact in every aspect of life, has also allowed their use in the health sector, making communication and long distance relationship possible, namely, between patients and the orthodontist, without the need for presential consultations. The use of videoconference systems allows real-time image sharing between the physician and the patient, also enabling the immediate clarification of questions raised by the patient or his/her parents, in case he/she is underage^[39].

The orthodontists and the elements who compose the clinical team must be trained in the use of the modern systems of communication based on the web, with acuteness concerning the assessment of their instructions and counter-instructions^[47]. Additionally, due to data protection, the transfer of personal files may require the installation of applications that guarantee the confidentiality in their transmission (text, images and videos) and that are only accessible after authorization by the administrator by login or sign-on^[48-50].

The physician must implement a health database in dentistry/orthodontics that provides support to the clinical decisions through digital media by setting up strict protocols, such as ^[51-55]: (*Level Ib, Class I*)

- Obtain the informed consent and the proper documentation;
- Patients must have the option to establish contact via e-mail in case they do not feel comfortable or are unable to carry out virtual consultations; or only via audio in case they opt for not using visual media;
- Choose the appropriate time, during working hours, to contact patients;
- Send all the financial information via e-mail as a piece of evidence;
- Keep the consultation formal, carrying it out in a professional environment, wearing a professional outfit.

In the framework of telemedicine, which procedures of the orthodontics consultation can be planned?

Answer: In the area of orthodontics, the use of teleconsultation may be suitable for different situations^[56-58]: (*Level IV, Class IIa*)

- First consultation for the partial establishment of the clinical history, to understand the reason for the consultation by the patient and, consequently, supplying useful information to the professional, which will allow a more focused and targeted approach in the subsequent clinical data gathering;
- Consultation intended to present the treatment plan by the orthodontist and of the budget by the team member who is in charge of the human resources area;
- Follow-up visit, this one with a wider applicability in treatments with aligners. However, it can also be used in treatments with fixed braces, particularly if certain methodologies have been established (i.e. optimal systems of brackets/arches, indirect gluing with individualization of the bracket for each tooth), allowing to lengthen the time period in between consultations and the eventual reduction of the treatment time. This type of follow-up can be performed in a synchronous (in real time with video) or asynchronous way (through the sending of photographs by messages or specific applications allowing to convey information from the patient to the orthodontist and from the orthodontist back to the patient);
- Consultation in the framework of interceptive orthodontics / dentofacial orthopedics. In some cases, it can also be speeded up with the due cooperation from the parents;
- In a generic way, the first consultations to which the patient is referred by the pediatric dentist, usually only observational, can also be carried out virtually.

What are the constraints in the access to the orthodontics consultation?

Answer: According to the previously published clinical guidelines, every procedure of access to the consultation must be observed, while stressing the importance of the triage questions to be asked at the appointment scheduling stage, of arriving on time for the consultation and coming to the appointment (preferably) all alone. The presence of an accompanying person in the waiting room and/or inside the consultation office must be minimized and reserved for children under 12 years old. Additionally, every patient must remain the least possible time in the waiting room, being desirable that they come in the

consultation office as soon as they arrive at the clinic. In those cases where we are dealing with an underage patient without an accompanying person in the consultation office and there are relevant instructions concerning the progress of the treatment (i.e. use of rubber bands, activation of an expander's screw, etc.), these must be transmitted to his/her guardian(s) in writing or through a telephone call in the shortest possible time, ideally the very same day of the consultation. If so wished, a means of communication (telephone contact, SMS, Whatsapp or e-mail) can be provided to the patients or their parents, allowing them to contact with the orthodontist or with a member of the orthodontic team, so that they can easily expose their doubts about the treatment and/or send digital images for assessment^[6, 15]. (*Level IIa, Class IIa*)

Key Points

- The educational strengthening to increase the patients' compliance with good practice of oral hygiene, as well as correct food habits, is key and must be carried out in every consultation, if necessary complemented by information leaflets. *(Level Ib, Class I)*
- Resorting to teleconsulting may prove an alternative in the schedule management, minimizing the patient's risk of exposure in the physical space of the consultation and maximizing the physician's response capacity, bearing, however in mind some constraints inherent in this type of consultation. *(Level Ib, Class I)*

The Stages of Peri-Intervention

Which type of PPE must be worn in an orthodontics consultation?

Answer: The PPE must be adapted to the type of clinical procedure. These can be generically divided into moderate risk interventions, where, due to their nature, aerosol generation is not expected, and high-risk interventions, where there is aerosol generation [22, 35, 36]. Procedures such as the removal of orthodontic composite and the enamel cleaning after the removal of the appliance increase the microbiological load and the production of aerosols. High-speed instruments that use air/water also produce more aerosols^[44,61-62]. (*Level IV, Class IIb*)

Moderate Risk Intervention	High-Risk Intervention
<ul style="list-style-type: none"> - Clinical exam; - Intra-oral and extra-oral photographic record; - Placement of removable braces; - Follow-up: replacement of metallic or elastic ligature ties; adjustment of the arches; removal and placement of the arches; change of aligner; activation of removable braces; activation of tooth-anchored braces (quad-helix, hyrax, etc); adaptation of surgical templates. 	<ul style="list-style-type: none"> - Placement of tooth-anchored fixed braces or components; - Placement of osteo-anchored devices (distractors; mini-implants; etc); - Repositioning of bracket and orthodontic band; - Orthodontic-surgical procedures; - Removal and placement of fixed appliances (complete fixed braces, palatal bar, lingual arch, placement of an orthodontic band, mini-implant); - Placement of bite blocks and other procedures using composite resins; - Interproximal dental abrasion (stripping); - Dental hygiene procedure in the framework of the orthodontic consultation.

What should the course of action regarding urgent situations or non-urgent appointments in orthodontics consultation be like?

Answer: During the epidemic period, the urgent situations in orthodontics must be addressed according to the regulations of control of the SARS-CoV-2 pandemic, and the first approach must be taken remotely. Every supplied advice must be recorded and guidance must be provided to the patients on how to manage minor emergencies at home. There are, however, several scenarios where you cannot leave a patient unassisted for a period longer than 10-12 weeks. The emergencies are manifold, the patient or his/her parents must send photographs or videos in order to enlighten the physician about the problem. It should be noted that the goal is to avoid urgent situations and not their treatment^[7, 64].

Removable appliance

If a removable brace is fractured or if the patient presents any discomfort while wearing it, we suggest the suspension of its use, in order to reduce the number of urgencies that cannot be immediately managed and the orthodontist must be contacted as soon as possible.

In case of fracture or loss of the aligners in use, the patient must wear the previous aligner or the following aligner, depending on the usage time of the broken/lost aligner.

In the event of a fracture or loss of the containment braces, if any of these events interferes with the stability of the treatment, we suggest the use of thermo-moldable plates easily found on e-commerce addresses or dedicated places, until the scheduling of an appointment to make the new containment is possible.

Fixed appliance

- Lip or jugal mucosa irritation caused by orthodontic braces:
 - Applying orthodontic wax or silicone on the bracket or the wire which is causing the irritation;
 - The orthodontic wax which may be accidentally swallowed is harmless;
 - The lesions on the mucosa or gum can be soothed by using a piece of cotton soaked in a small amount of topical anesthetic, applied daily on the ulcerated surface. There may be the need to apply it again.
- Elastic ligature tie become detached from the bracket:
 - During the brushing or while eating, the bracket's ligature tie may get loose;
 - The ligature tie may be placed back again with sterilized tweezers around the whole bracket's structure;
 - In case the patient is unable to reposition the ligature tie, this one can be removed using sterilized tweezers.
- Metallic ligature tie become detached from the bracket, or irritating the lips or the jugal mucosa:
 - If the ligature tie is loose, use sterilized tweezers to remove it;
 - If the ligature tie is not loose, but if it is irritating the mucosae, use a cotton swab or that little rubber that exists at the end of a pencil to bend it.
- Loose or broken elastic chain:
 - Remove this segment of the elastic chain with sterilized tweezers or cut it with a sterilized cutting instrument (i.e. nail plier, nail clipper).

- Loose orthodontic component (bracket, tube or band):
 - In case a bracket is loose but keeps in position, it can be left as it is. If, on the other hand, it moves, the patient or his/her parents can remove it with sterilized tweezers;
 - In case the loose bracket is the support of intermaxillary rubber bands, their use must be interrupted;
 - If the last element of the braces is detached, it can be moved, by making it slide along the arch, in case the caregiver manages to perform it safely and there is no distal bending. Alternatively, the patient can cut the arch at the last fixed element using a sterilized nail plier or nail clipper, removing the detached adjacent structure.
- Protruding arch at the end of the fixed braces:
 - Using a cotton swab or that little rubber that exists at the end of a pencil, push the arch in order to flatten it against the tooth. If that is not possible, we can recommend the orthodontic wax as a protection;
 - Sometimes, the arch is protruding on one of its ends after having slid all along the braces. Should this happen, you must encourage the patient to reposition the arch making use of sterilized tweezers, so that it is steady and comfortable on both sides;
 - In case the arch is irritating the oral mucosa, you must ask the patient to cut the excess of arch with a sterilized cutting instrument, like a nail plier or a nail clipper. At this point, the caregiver must put a gauze all around that area in order to reduce the possibility that the patient swallows the excess of cut-off arch. It may also prove necessary to apply orthodontic wax to provide comfort to the irritated area.
- Swallowed braces' or bracket's element:
 - Most orthodontic elements of little dimension, like brackets, when swallowed, pass through the digestive tract with no complications;
 - If an element has been swallowed, you must confirm whether the patient has had trouble breathing or cough suddenly after swallowing the object. In the event of a sudden shortness of breath or cough after swallowing it, the patient must head for the service of hospital emergency, a clinical and radiographic assessment being advised.

- Traumatic injury to the gum caused by the orthodontic wire which causes intense pain/infection:
 - Using a sterilized cutting instrument, cut the portion of the arch and remove it using sterilized tweezers. In case you suspect of a periodontal abscess, an urgent consultation must be scheduled in order to rule out the causal factor. If that proves impossible, you must prescribe an anti-inflammatory/analgesic and, where necessary, antibiotic therapy.

Other situations:

- Fractured fixed containment:
 - If the whole fixed containment is detached, it must be removed by the patient. Where possible, the patient must wear his/her removable containment braces;
 - If the containment is loose in only one or two dental pieces, the patient can:
 - Try and push the arch so it contacts with the teeth, in the area where the containment is not adhered;
 - Cut the exposed not adhered part using a sterilized cutting instrument;
 - If only a small portion of the containment is adhered, use sterilized tweezers to remove all the containment. If that proves impossible, the containment must be cut off, leaving the portion adhered in the mouth.
- Fractured or detached fixed expander, lingual or palatal arch:
 - If the expander, lingual arch or palatal bar is partially adhered and still present in the mouth, it must be put back in its correct position and the activations must be interrupted;
 - In case the device has entirely come out, it must be kept for subsequent placement, as needed.
- Fractured mandibular propulsion braces:
 - If the device is completely fractured and the shaft cannot be placed in the spring, the braces' loose portion must be removed.
- Fixed/removable braces activated at home (i.e. face mask, extra-oral traction, quad-helix, hyrax, pendulum...):
 - In a preventive way, the suspension of their use/activation might be recommended until the presential consultation is possible, in order to avoid a possible emergency;

- Alternatively, the patient can arrange with the orthodontist to send him/her images showing the progress of the treatment in certain periods of time, depending on the mechano-therapy in question^[6,15,21,47,65,66].

(Level IIa, Class I)

How should the disinfection of the removable braces be performed?

Answer: The handling braces to be placed at the consultation must be carefully done and their correct disinfection guaranteed^[67,68]: *(Level IIa, Class I)*

- Metallic orthodontic braces (quad-helix, for instance) must be submerged in alcohol at 70% for 5 minutes and later rinsed;
- Removable orthodontic braces without metallic components must be submerged in sodium hypochlorite at 1% for 10 minutes;
- Removable orthodontic braces with metallic components must be submerged in hydrogen peroxide at 1 %, for 10 minutes.

How should the arches be disinfected in the course of the extraoral manipulation?

Answer: Before placing the orthodontic arches, they must be submerged in alcohol at 70% for 1 minute. *(Level IV, Class IIb)*

How should steel wires, elastic chains and elastomers be manipulated?

Answer: Since they are elements with a high risk of cross contamination, they must be sectioned into small portions before being handled in the mouth and the remainder must be disposed off^[68, 69]. *(Level IIb, Class IIa)*

Key Points

- The PPE must be adapted to the type of clinical procedure in question. It can be generically divided into moderate risk interventions, where, due to their nature, aerosol generation is not expected, and high-risk interventions, where there is aerosol generation. *(Level IV, Classe IIb)*
- Metallic orthodontic braces (i.e. quad-helix) must be submerged in alcohol at 70 % for 5 minutes and rinsed afterwards. *(Level III, Classe IIa)*
- Removable orthodontic braces without metallic components must be submerged in sodium hypochlorite at 1 % for 10 minutes. *(Level III, Classe IIa)*
- Removable orthodontic braces with metallic components must be submerged in hydrogen peroxide at 1 % for 10 minutes. *(Level III, Classe IIa)*
- Before being placed, the orthodontic arches must be submerged in alcohol at 70 % for 1 minute. *(Level IV, Classe IIb)*
- The steel wires, elastic chains and elastomers, since they are elements with a high risk of cross contamination, must be sectioned into small portions before being handled in the mouth and the remainder must be disposed of. *(Level III, Classe IIa)*

The Stages of Post-Intervention

In order to avoid the risk of nosocomial contamination, and to protect the patient and the orthodontic team, the material and the orthodontic instruments must always be disinfected and sterilized. The instruments that come into direct contact with the patient's blood or saliva, like the band pushers, band removers or ligature tie directors constitute a high risk of contamination in case they are not sterilized [6] . The same can be said with respect to the orthodontic bands, photograph retractors, photographic mirrors and tungsten drills used to remove the resin (in the removal of the fixed appliances). An orthodontic practice with an inappropriate handling and disinfection of these instruments and materials puts the control of the nosocomial infection at risk. Therefore, every instrument used during the consultation, as well as those that have not been used, but having still been exposed to the environment, must be immediately disinfected and sterilized. Both these instruments and the disposable material must always be considered as infected material^[15,70].

Which procedure should be adopted in the sterilization of the orthodontic cutting pliers?

Answer: The orthodontic pliers can be sterilized by autoclaving, dry heat, chemical vapor or ethylene oxide. As far as the pliers containing plastic elements are concerned, the sterilization by ethylene oxide is the only method considered to be effective. However, this method implies very long procedures and it is more costly. The sterilization of orthodontic ligature tie cutting pliers made of stainless steel does not present significant differences when performed by autoclaving or by dry heat. Therefore, the autoclave, the most commonly used method of sterilization in dental clinics, can be used without any significant negative effects to this type of pliers.

After used, the plier must be washed, disinfected, dried and lubricated in the articulation areas, then put into sleeves and sterilized. While cleaning manually, it must not be rubbed with hard objects, since they might destroy the instrument's surface and increase the risk of oxidation. When cleaning it with a thermal disinfection equipment, you must use a neutral pH enzymatic detergent, but when cleaning manually, we recommend the use of a neutral or mild alkaline detergent (between pH 7 and 10).

The ultrasound cleaning equipment requires the chemical disinfectants to be mixed according to the manufacturer's instructions and prepared on a daily basis in order to avoid undesired effects induced by evaporation and contamination. The immersion in ultrasound tanks cannot exceed the maximum treatment time nor the temperature recommended by the manufacturer (for instance, you must never leave the instruments in the bath overnight or over the weekend, nor allow the temperature to exceed 25°C).

In the treatment prior to the placement in sterilization sleeves, the pliers must be lubricated, by applying oil specific for these instruments, in the articulation areas and in other critical points, like the blade, spring or hard metal cutting inserts – tungsten carbide, and they must be opened and closed multiple times. When you put the pliers in sleeves, these must have their shafts fully open.

Sterilization by autoclaving is typically performed at 134°C, lower than that mentioned by some manufacturers, 180°C, at which point, softening effects of the cutting areas may start to occur^[63,68,71-75]. (*Level IIa, Class IIa*)

What care should you have for the other instruments and specific orthodontic material in order to reduce the risk of nosocomial infection?

Answer: Orthodontic bands – The bands that have already been tried on in the mouth, but that have not been used, must be disinfected and sterilized by autoclaving^[6,15,63,70].

Brackets' positioning star – If the device is metallic, it must be cleaned with a dressing soaked in alcohol at 70%, although you should preferably use disposable devices^[6,15,70].

Steel wires, arches, brackets and portions of orthodontic braces removed from the mouth – they should be treated as infected material and disposed of^[6,15,70].

Mini-implant – The majority of manufacturers already sell the mini-implants in sterilized individual sachets. Otherwise, you must always follow the manufacturer's recommendations to ensure effectiveness of the sterilization process.

The mini-implants must not be retrieved, since they may suffer alterations to their surface characteristics. Therefore, their reuse is not recommendable, since there is not enough scientific evidence on a series of variables which may affect their resistance to fracture^[76,77].

Lip retractors – Their washing and disinfection must be performed in an ultrasound tank filled with a disinfectant solution, followed by sterilization in autoclaved inside sleeves afterwards^[6,15,70]. (*Level IIa, Class IIa*)

How can we avoid cross infection with the photo equipment?

Answer: The photo equipment, usually used in dentistry to document and help with diagnosis, is a kind of material that is not part of the medical electronic equipment and, for that reason, it has not been designed to be disinfected nor withstand the corrosive effect of most disinfectants used in dentistry. Hence, the simplest thing to do is to use protective barriers meant to protect the several components of the photo equipment.

- Body of the reflex camera;
- Macro objective;
- Ring flash or twin flashes;
- UV filter acting as a protector of the objective lens;
- Intraoral mirrors.

The body of the reflex camera and the macro objective can be protected with a 25 µm thick polyethylene bag with an approximate dimension of 38 x 66 cm (30 l).

Secure the bag's opening between the ring flash and the objective, in order to secure the bag between these two. If you use twin flashes, you must use a bigger bag (60 l).

The polyethylene bag makes it harder to access the eyepiece of the camera's body when you wish to view the field in focus and, for that reason, you must use the LCD monitor found in most digital cameras, shifting the camera to Live View mode. In order to use this function, you must resort to a means of additional lighting, like the lamp of the dental equipment, so you can adapt the objective's speed and/or opening to the amount of light which is necessary to a correct viewing through the LCD. Most cameras let you set the brightness of the LCD monitor and some software that exists in the camera also allows to eliminate the influence of this additional light in the final photo^[78].

As an alternative to the polyethylene bag, you can use an autoclaved sterilization sleeve (paper/polyester or laminated polypropylene), making an opening in the polyester/polypropylene area through which the objective can pass and then fixing the ring flash. This method protects the body and a part of the objective, leaving the opening of the sleeve on the back of the camera's body, in order to facilitate the viewing through the eyepiece. However, this method does not effectively protect the objective nor the ring flash, requiring a chemical disinfection before and after every single use^[79].

The use of a UV filter acting as a protector of the objective lens allows to minimize the effect of the disinfectant on the objective lens. Thus, you may use isopropyl alcohol spray at 70% directly on the filter or, in case you prefer, an appropriate cloth or wipe soaked in alcohol^[79,80]. (*Level IIa, Class I*)

How can you disinfect intraoral mirrors?

Answer: The most effective method to disinfect and sterilize intraoral mirrors is the washing with detergent and running water, followed by their placement in an ultrasound tank filled with a disinfectant solution, and their subsequent sterilization by autoclaving. Before being put in the sleeves, they must be properly dried and wrapped in a fabric/nonfabric to minimize the appearance of stains on their surface. However, even so, the sterilization by autoclaving damages, at the end of some cycles, the mirror's superficial layer, leaving it stained. Another effective method, according to Marquezan et al., is the use of a detergent solution of chlorhexidine for 3 minutes, followed by a washing with distilled water - this one being a more effective method than the use of ethyl alcohol at 70% for 3 minutes. However, due to the possible ineffectiveness of chlorhexidine against SARS Cov-2, the recommendation is that, although mirrors are considered semi-critical materials, without any evidence to the contrary, these must be treated like critical materials and subjected to sterilization by autoclaving^[78,79,80]. (*Level IIa, Class I*)

Key Points

- **Orthodontic bands** – The bands that have already been tried on in the mouth, but that have not been used, must be disinfected and sterilized by autoclaving. *(Level IIa, Class IIa)*
- **Brackets' positioning star** – if the device is metallic, it must be cleaned with a compress soaked in alcohol at 70%, although you should preferably use disposable devices. *(Level IIa, Class IIa)*
- **Steel wires, arches, brackets and portions of orthodontic braces removed from the mouth** – they should be treated as infected material and disposed of. *(Level IIa, Class IIa)*
- **Mini-implant** – The majority of manufacturers already distribute the mini-implants in sterilized individual sachets. Otherwise, you must always follow the manufacturer's recommendations to secure the effectiveness of the sterilization process. *(Level IIa, Class IIa)*
- **Lip retractors** – Their washing and disinfection must be performed in an ultrasound tank filled with a disinfectant solution, being sterilized and autoclaved in sleeves. *(Level IIa, Class IIa)*
- The body of the reflex camera and the macro objective can be protected with a 25 µm thick polyethylene bag with an approximate dimension of 38 x 66 cm (30 l). *(Level IIa, Class I)*
- The use of a UV filter acting as a protector of the objective lens allows to minimize the effect of the disinfectant on the objective lens. Therefore, you can use isopropyl alcohol spray at 70% directly on the filter or, in case you prefer, an appropriate cloth or wipe. *(Level IIa, Class I)*
- The most effective method to disinfect and sterilize intraoral mirrors is the washing with detergent and running water, followed by their placement in an ultrasound tank filled with a disinfectant solution, and subsequent sterilization by autoclaving. *(Level IIa, Class I)*

Conclusion

The impact of the pandemic on Dentistry, as well as on orthodontics, cannot be valued, and more serious consequences should be expected to be exacerbated according to the expected financial instability ahead. Therefore, the growing use of digital orthodontics and the patient's monitoring through virtual consultations must be faced as a reality and encouraged in the future.

For further information, please refer to the full document titled *COVID-19. Clinical Guidelines - Dentistry*^[1,81].

Acknowledge

The authors would like to acknowledge NSK, Tokyo, Japan for supporting the translation of this Clinical Guidelines.

Bibliography

1. Guerra, F., et al., COVID-19. Normas de Orientação Clínica - Medicina Dentária. Universidade de Coimbra, 2020. ISBN: 978-989-26-1985-9. DOI: 10.14195/978-26-1985-9.
2. National Institute for Health and care Excellence, Interim process and methods for developing rapid guidelines on COVID-19. Published date: 20 March 2020. <https://www.nice.org.uk/process/pmg35/chapter/scoping> (acedido a 11 de março de 2021).
3. WHO, Novel Coronavirus(2019-nCoV), Situation Report - 11. https://www.who.int/docs/default-source/coronaviruse/situation-reports/20200131-sitrep-11-ncov.pdf?sfvrsn=de7c0f7_4 (acedido a 03 junho 2020). 2020.
4. Peditto, M., et al., Dentistry during the COVID-19 Epidemic: An Italian Workflow for the Management of Dental Practice. *Int J Environ Res Public Health*, 2020. 17(9). DOI: 10.3390/ijerph17093325.
5. Peng, X., et al., Transmission routes of 2019-nCoV and controls in dental practice. *Int J Oral Sci*, 2020. 12(1): p. 9.
6. Turkistani, K.A., Precautions and recommendations for orthodontic settings during the COVID-19 outbreak: A review. *Am J Orthod Dentofacial Orthop*, 2020. 158(2):175-181. DOI: 10.1016/j.ajodo.2020.04.016. Epub 2020 May 13.
7. Turkistani, K.A. and Turkistani, K.A., Dental Risks and Precautions during COVID-19 Pandemic: A Systematic Review. *J Int Soc Prev Community Dent*, 2020. 10(5):540-548. DOI: 10.4103/jispcd.JISPCD_295_20.
8. Kaur, H., et al., Appropriate orthodontic appliances during the COVID-19 pandemic: A scoping review. *J Oral Biol Craniofac Res*, 2020.10(4):782-787. DOI: 10.1016/j.jobcr.2020.10.014.
9. Chan, J.F., et al., A familial cluster of pneumonia associated with the 2019 novel coronavirus indicating person-to-person transmission: a study of a family cluster. *Lancet*, 2020. 395(10223):514-523. DOI: [https://doi.org/10.1016/S0140-6736\(20\)30154-9](https://doi.org/10.1016/S0140-6736(20)30154-9).
10. Lu, X., et al., SARS-CoV-2 Infection in Children. *N Engl J Med*, 2020. 382(17):1663-1665. DOI: 10.1056/NEJMc2005073.
11. Rothe, C., et al., Transmission of 2019-nCoV Infection from an Asymptomatic Contact in Germany. *N Engl J Med*, 2020. 382(10): p. 970-971. DOI: 10.1056/NEJMc2001468.
12. Zhang, W. and Jiang, X., Measures and suggestions for the prevention and control of the novel coronavirus in dental institutions. *Frontiers of Oral and Maxillofacial Medicine*, 2020. 2.
13. Wu, Z. and McGoogan, J.M., Characteristics of and Important Lessons From the Coronavirus Disease 2019 (COVID-19) Outbreak in China: Summary of a Report of 72314 Cases From the Chinese Center for Disease Control and Prevention. *JAMA*, 2020.
14. Zimmermann, P. and Curtis, N., Coronavirus Infections in Children Including COVID-19: An Overview of the Epidemiology, Clinical Features, Diagnosis, Treatment and Prevention Options in Children. *Pediatr Infect Dis J*, 2020. 39(5):355-368. DOI: 10.1097/INF.0000000000002660.

15. Suri, S., et al., Clinical orthodontic management during the COVID-19 pandemic. *Angle Orthod*, 2020. 90(4):473-484. DOI: 10.2319/033120-236.1.
16. Popat, H., et al., Management of orthodontic emergencies in primary care - self-reported confidence of general dental practitioners. *Br Dent J*, 2016. 221(1):21-4. DOI: 10.1038/sj.bdj.2016.495.
17. Caprioglio, A., et al., Management of orthodontic emergencies during 2019-NCOV. *Prog Orthod*, 2020. 21(1): p. 10. DOI: 10.1186/s40510-020-00310-y
18. Antezack, A. and Monnet-Corti, V., Oral and periodontal hygiene in orthodontic patients. *Orthod Fr*, 2018. 89(2):181-190. DOI: 10.1051/orthodfr/2018015.
19. Huang, J., et al., Effects of motivational methods on oral hygiene of orthodontic patients: A systematic review and meta-analysis. *Medicine (Baltimore)*, 2018. 97(47):e13182. DOI: 10.1097/MD.00000000000013182.
20. Mallineni, S.K., et al., Coronavirus disease (COVID-19): Characteristics in children and considerations for dentists providing their care. *Int J Paediatr Dent*, 2020. 30(3):245-250. DOI: 10.1111/ipd.12653.
21. Wang, Y., et al., Oral Health Management of Children during the Epidemic Period of Coronavirus Disease 2019. *Sichuan Da Xue Xue Bao Yi Xue Ban*, 2020. 51(2): p. 151-154. DOI: 10.12182/20200360101.
22. Meeran, N.A., Iatrogenic possibilities of orthodontic treatment and modalities of prevention. *J Orthod Sci*, 2013. 2(3):73-86. DOI: 10.4103/2278-0203.119678.
23. Peixoto, I.T., et al., Evaluation of home disinfection protocols for acrylic baseplates of removable orthodontic appliances: A randomized clinical investigation. *Am J Orthod Dentofacial Orthop*, 2011. 140(1):51-7. DOI: 10.1016/j.ajodo.2009.12.036.
24. Lopes Vasconcelos, G.L., et al., In Vitro Antimicrobial Activity of Effervescent Denture Tablets on the Components of Removable Partial Dentures. *Int J Prosthodont*, 2020. 33(3): 315-320. DOI: 10.11607/ijp.6436.
25. Sharma R, et al., Nutritional Guidelines for Orthodontic Patients. *The Internet Journal of Nutrition and Wellness*. 2009 Volume 10 Number 2.
26. Centers for Disease Control and Prevention. Guidelines for Preventing the Transmission of Mycobacterium tuberculosis in Health-Care Settings, 2005. <https://www.cdc.gov/mmwr/preview/mmwrhtml/rr5417a1.htm>. (acedido a 19 de abril de 2020).
27. Administração Central do Sistema de Saúde. Especificações Técnicas para Instalações de AVAC – ET 06/2008. http://www.acss.min-saude.pt/wp-content/uploads/2016/09/Especificacoes_Tecnicas_06_2008.pdf. (acedido a 19 de abril de 2020).
28. Centers for Disease Control and Prevention. Guidelines for Environmental Infection Control in Health-Care Facilities (2003). Appendix B. Air. <https://www.cdc.gov/infectioncontrol/guidelines/environmental/appendix/air.html#tableb1>. (acedido a 19 de abril de 2020).
29. New York State Department of Health. New York State Department of Health. 2017. <https://www.health.ny.gov/facilities/cons/docs/3-14-0.pdf> (acedidos a 19 de abril de 2020).

30. Veterans Affairs. Dental Service design guide. 2014. <https://www.cfm.va.gov/til/dGuide/dgDental.pdf>. (acedido a 19 de abril de 2020).
31. American Association of Orthodontists. COVID-19 Resources for Orthodontists. <https://www1.aaoinfo.org/covid-19/> (acedido a 03 junho 2020).
32. Harrel, S.K. and Molinari, J., Aerosols and splatter in dentistry: a brief review of the literature and infection control implications. *J Am Dent Assoc*, 2004. 135(4):429-37. DOI: 10.14219/jada.archive.2004.0207.
33. Helmis, C.G., et al., Indoor air quality in a dentistry clinic. *Sci Total Environ*, 2007. 377(2-3): 349-65. DOI: 10.1016/j.scitotenv.2007.01.100.
34. Li, Y., et al., Role of ventilation in airborne transmission of infectious agents in the built environment - a multidisciplinary systematic review. *Indoor Air*, 2007. 17(1):2-18. DOI: 10.1111/j.1600-0668.2006.00445.x.
35. Raghunath, N., et al., Aerosols in Dental Practice- A Neglected Infectious Vector. *Microbiology Research Journal International*, 2016. 14. DOI: 10.9734/BMRJ/2016/24101.
36. Qian, H. and Zheng, X., Ventilation control for airborne transmission of human exhaled bio-aerosols in buildings. *J Thorac Dis*, 2018. 10(Suppl 19):S2295-S2304. DOI: 10.21037/jtd.2018.01.24.
37. OSHA, Guidance on Preparing Workplaces for COVID-19. 2020: p. 18-20.
38. WHO, Infection prevention and control during health care when novel coronavirus (nCoV) infection is suspected Interim guidance. ISBN 978-92-4-000091-9. 2020.
39. Cotrin, P., et al. Urgencies and emergencies in orthodontics during the coronavirus disease 2019 pandemic: Brazilian orthodontists' experience. *Am J Orthod Dentofacial Orthop*, 2020. 158(5):661-667. DOI: 10.1016/j.ajodo.2020.06.028.
40. Llandro, H., et al., Evaluating splatter and settled aerosol during orthodontic debonding: implications for the COVID-19 pandemic. *Br Dent J*, 2021. 8:1-7. DOI: 10.1038/s41415-020-2503-9.
41. Din, A.R., et al., Quantitative analysis of particulate matter release during orthodontic procedures: a pilot study. *Br Dent J*, 2020. 12:1-7. DOI: 10.1038/s41415-020-2280-5.
42. Bustati, N. and Rajeh, N., The impact of COVID-19 pandemic on patients receiving orthodontic treatment: An online questionnaire cross-sectional study. *J World Fed Orthod*, 2020. 9(4):159-163. DOI: 10.1016/j.ejwf.2020.10.003.
43. García-Camba, P., et al., Changes in orthodontics during the COVID-19 pandemic that have come to stay. *Am J Orthod Dentofacial Orthop*, 2020. 158(4):e1-e3. DOI: 10.1016/j.ajodo.2020.07.014.
44. Guo, Y., et al., Control of SARS-CoV-2 transmission in orthodontic practice. *Am J Orthod Dentofacial Orthop*, 2020. 158(3):321-329. DOI: 10.1016/j.ajodo.2020.05.006.
45. Taxa de penetração de telemóveis em Portugal nos 96,5%. <https://tek.sapo.pt/mobile/equipamentos/artigos/taxa-de-penetracao-de-telemoveis-em-portugal-nos-965> (acedido a 03 junho 2020).

46. ANACOM, 7,2 milhões de pessoas em Portugal usam Internet móvel. <https://www.anacom.pt/render.jsp?contentId=1462951> (acedido a 03 junho 2020).
47. Caprioglio, A., et al., Management of orthodontic emergencies during 2019-NCOV. *Prog Orthod*, 2020. 21(1):10. DOI: 10.1186/s40510-020-00310-y.
48. Cook, J., et al., Online orthodontic advice: a protocol for a pilot teledentistry system. *J Telemed Telecare*, 2001. 7(6):324-33. DOI: 10.1258/1357633011936958.
49. Wallwiener, M., et al., Impact of electronic messaging on the patient-physician interaction. *J Telemed Telecare*, 2009. 15(5):243-50. DOI: 10.1258/jtt.2009.090111.
50. Adly, M.S., et al., Assessment of early orthodontic treatment on functional shifts by telemonitoring mandibular movements using a smart phone. *J Telemed Telecare*, 2020. 26(3): 150-160. DOI: 10.1177/1357633X18800876.
51. American Dental Association. COVID-19 Coding and Billing Interim Guidance: Virtual Visits. https://success.ada.org/~media/CPS/Files/COVID/ADA_COVID_Coding_and_Billing_Guidance.pdf (acedido 03 junho 2020).
52. Greenhalgh, T., et al., Virtual online consultations: advantages and limitations (VOCAL) study. *BMJ Open*, 2016. 6(1):e009388. DOI: 10.1136/bmjopen-2015-009388.
53. Kotantoula, G., et al., Teleorthodontics. *Am J Orthod Dentofacial Orthop*, 2017. 151(1): 219-221. DOI: 10.1016/j.ajodo.2016.10.012.
54. Estai, M., et al., A systematic review of the research evidence for the benefits of teledentistry. *J Telemed Telecare*, 2018. 24(3):147-156. DOI: 10.1177/1357633X16689433.
55. Bakhai, M., et al., Using Online Consultations In Primary Care. NHS England, 2020.
56. American Association of Orthodontists. Onboarding New Patients with Virtual Consultations. <https://www1.aaoinfo.org/onboarding-new-patients-with-virtual-consultations/> (acedido a 03 junho 2020).
57. Maret, D., et al., Integration of telemedicine into the public health response to COVID-19 must include dentists. *Int Endod J*, 2020. 53(6):880-881. DOI: 10.1111/iej.13312.
58. Rockwell, K.L. and Gilroy, A.S., Incorporating telemedicine as part of COVID-19 outbreak response systems. *Am J Manag Care*, 2020. 26(4):147-148. DOI: 10.37765/ajmc.2020.42784.
59. COVID-19: Procedimentos em Clínicas, Consultórios ou Serviços de Saúde Oral dos Cuidados de Saúde Primários, Setor Social e Privado. Orientação 022/2020 de 01/05/2020.
60. Viridi MK, et al., The Debate: What Are Aerosol-Generating Procedures in Dentistry? A Rapid Review. *JDR Clin Trans Res*, 2021. DOI: 10.1177/2380084421989946.
61. Innes, N., et al., A systematic review of droplet and aerosol generation in dentistry. *J Dent*, 2020. 23;105:103556. DOI: 10.1016/j.jdent.2020.103556.
62. Koletsis, D., et al., Interventions to Reduce Aerosolized Microbes in Dental Practice: A Systematic Review with Network Meta-analysis of Randomized Controlled Trials. *J Dent Res*, 2020. 99(11):1228-1238. DOI: 10.1177/0022034520943574.
63. Bizzoca, M.E., et al., An innovative risk-scoring system of dental procedures and safety protocols in the COVID-19 era. *BMC Oral Health*, 2020. 20(1):301. DOI: 10.1186/s12903-020-01301-5.

64. Saltajim, H. and Sharaf, K.A., COVID-19 and Orthodontics—A Call for Action. *American Journal of Orthodontics & Dentofacial Orthopedics*, 2020. 158(1): 12–13. DOI: <https://doi.org/10.1016/j.ajodo.2020.04.006>.
65. Nanda, R. and Kapila, S., *Current Therapy in Orthodontics*. ISBN: 9780323185820.
66. Falahchai, M., et al.. Dental care management during the COVID-19 outbreak. *Spec Care Dentist*, 2020. 40(6):539-548. DOI: 10.1111/scd.12523.
67. da Silva, F.C., et al., Effectiveness of six different disinfectants on removing five microbial species and effects on the topographic characteristics of acrylic resin. *J Prosthodont*, 2008. 17(8): 627-33. DOI: 10.1111/j.1532-849X.2008.00358.x.
68. Kalra, S., et al., *Infection Control in Orthodontics*. *Journal of Orthodontics and Endodontics*, 2015.
69. Pithon, M.M., et al., Sterilizing elastomeric chains without losing mechanical properties. Is it possible? *Dental Press J Orthod*, 2015. 20(3):96-100. DOI: 10.1590/2176-9451.20.3.096-100.oar.
70. Batra, P. and Jyothikiran, H., Tips for maintaining sterilization in your orthodontic work station. *Int J Orthod Milwaukee*, 2014. 25(2):21-30. PMID: 25109055.
71. Dentaureum. <https://www.dentaureum.de/eng/about-covid-19-36170.aspx> (acedido a 03 junho 2020).
72. Tungsten Carbide vs Tool Steel Orthodontic Pliers. <https://diatechusa.com/blog/tungsten-carbide-steel-pliers/> (acedido a 03 junho 2020).
73. Mazzocchi, A., *Orthodontic pliers and sterilization procedures*. *Virtual Journal of Clinical Orthodontics*, 1996.
74. Vendrell, R.J., et al., Effect of steam versus dry-heat sterilization on the wear of orthodontic ligature-cutting pliers. *Am J Orthod Dentofacial Orthop*, 2002. 121(5):467-71. DOI: 10.1067/mod.2002.122175.
75. Melo Neto, C.L.M., et al., SARS-CoV-2 and Dentistry-Review. *Eur J Dent*, 2020. 14(S 01):S130-S139. DOI: 10.1055/s-0040-1716438.
76. Cope, J.B., et al., *Guidelines for miniscrew implant sterilization and use*. *Orthodontic Products Staff*, 2009.
77. Akyalcin, S., et al., Effects of repeated sterilization cycles on primary stability of orthodontic mini-screws. *Angle Orthod*, 2013. 83(4):674-9. DOI: 10.2319/082612-685.1.
78. <http://dentist.camera/hygienic-procedures-in-dentistry-for-covid-19-cross-infection-control-on-photographic-equipment/> (acedido a 22 junho de 2020).
79. Vasileva, R., et al., Protocol for sterile conditions using dental photography. *MedInform*, 2017.
80. Freitas, A.O.A., et al., Infection control in dentistry: how to clean photographic mirrors? *Rev. Saúde*, 2013.
81. Guerra, F., et al., COVID-19. Normas de Orientação Clínica - Medicina Dentária. Universidade de Coimbra, 2021. *In press*.